



**PRESENTING CLINICAL SIGNS**

History: Recheck DMVD. Doing well.. Currently receiving Vetmedin 2.5 mg BID. BP 102/77.  
Sedated for exam with acepromazine and butorphanol.

DATE

2/16/22

**ECHOCARDIOGRAPHIC FINDINGS**

2D, M-mode, and Doppler study. This exam is compared to the one performed 8/10/21.

PERFORMED BY:

Dr. Brian Barnes

INTERPRETED BY

Keith Blass, DVM,  
MS, DACVIM  
(Cardiology)

There is moderate left atrial dilation. The mitral valve leaflets are thickened, and a moderate jet of eccentric mitral regurgitation is present. MR velocity does not suggest the presence of systemic hypertension. There is moderate left ventricular dilation. Left ventricular systolic function is hyperdynamic. The aorta and aortic valve are normal. Right atrial and right ventricular dimensions are normal. The tricuspid valve leaflets are mildly thickened, and a mild jet of tricuspid regurgitation is present. TR velocity does not suggest the presence of pulmonary hypertension. The pulmonary artery and pulmonic valve appear normal, though trace pulmonic insufficiency is present. No pericardial effusion or cardiac masses are seen.

ECG during echo: Sinus arrhythmia

PATIENT

Luci Carlson

SPECIES

Canine

LA - 38.8 mm (prev. 38.8 mm)  
LVIDd - 39.3 mm (prev. 38.7 mm)  
LVIDs - 20.6 mm (prev. 21.5 mm)  
FS - 47.6% (prev. 44.4%)  
LVOT - 1.81 m/s (prev. 1.91 m/s)  
RVOT - 0.98 m/s (prev. 1.20 m/s)  
MR - 4.50 m/s (prev. 4.94 m/s)  
TR - 2.71 m/s (prev. 2.67 m/s)

**ASSESSMENT/RECOMMENDATIONS**

Degenerative mitral and tricuspid valve disease

BREED

Cocker Spaniel

This examination demonstrates no progression of Luci's mitral valve disease over the past 6 months. As such, Luci's current risk for the development of left-sided congestive heart failure has not increased, however, given the presence of moderate left atrial dilation, careful monitoring of her respiratory rate/effort is still recommended.

SEX

FS

Luci now has mild thickening of her tricuspid valve leaflets consistent with degenerative valve disease. The resulting tricuspid regurgitation is mild, and Luci's tricuspid valve disease appears to be well-compensated.

AGE

11 y

No change in cardiac therapy appears to be warranted at this time.

A recheck echocardiogram is recommended in 6-9 months. Thoracic radiographs are recommended if Luci develops new respiratory clinical signs.

WEIGHT

9.65 kg

HOSPITAL NAME

Westview VH

REFERRING VET

Dr. Barnes



DATE

2/16/22

PERFORMED BY:

Dr. Brian Barnes

INTERPRETED BY

Keith Blass, DVM,  
MS, DACVIM  
(Cardiology)

PATIENT

Luci Carlson

SPECIES

Canine

BREED

Cocker Spaniel

SEX

FS

AGE

11 y

WEIGHT

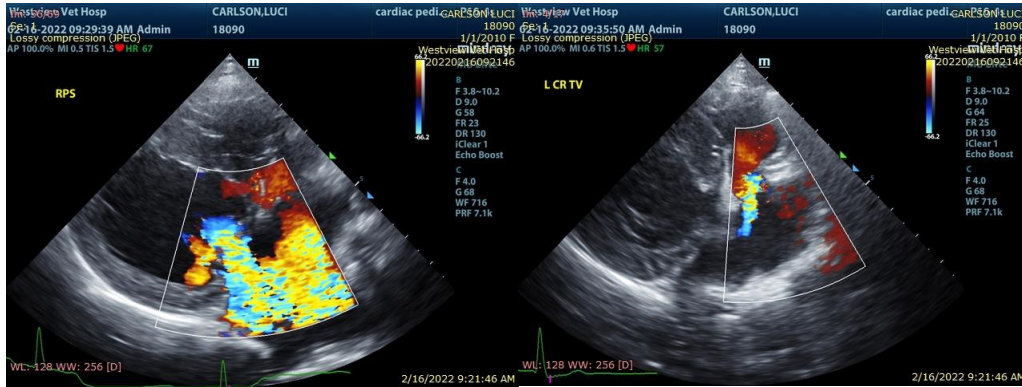
9.65 kg

HOSPITAL NAME

Westview VH

REFERRING VET

Dr. Barnes



The information and recommendations provided are based on the images presented by the referring veterinarian. No evaluation can be communicated regarding pathology that was not visible in the image/video clips provided.

Thank you for this referral. If the clinical or image interpretation does not parallel your findings or if I can be of any further assistance please contact me.

Keith Blass, DVM, MS, DACVIM (Cardiology)  
KeithBlass@gmail.com  
631-804-5754